


OCLUZIILE INTESTINALE DOBÎNDITE LA COPII

*Catedra chirurgie, anesteziologie, reanimare, ortopedie și traumatologie
pediatrică*

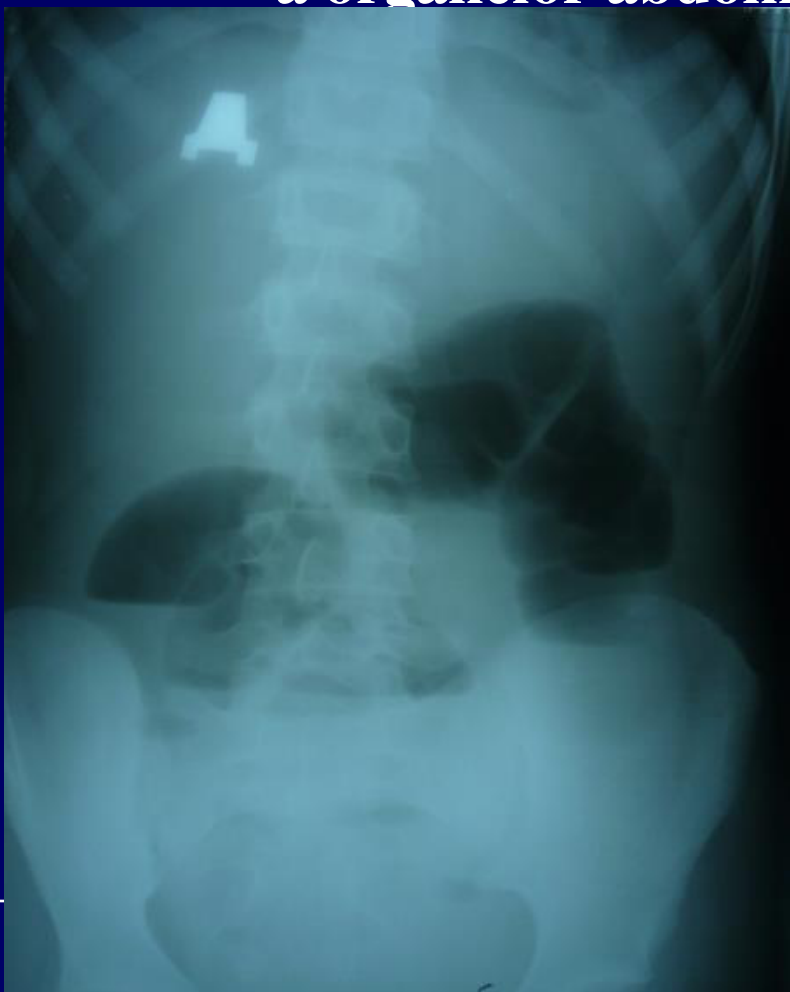Centrul Național Științifico-practic de Chirurgie Pediatrică

“Acad. Natalia Gheorghiu”

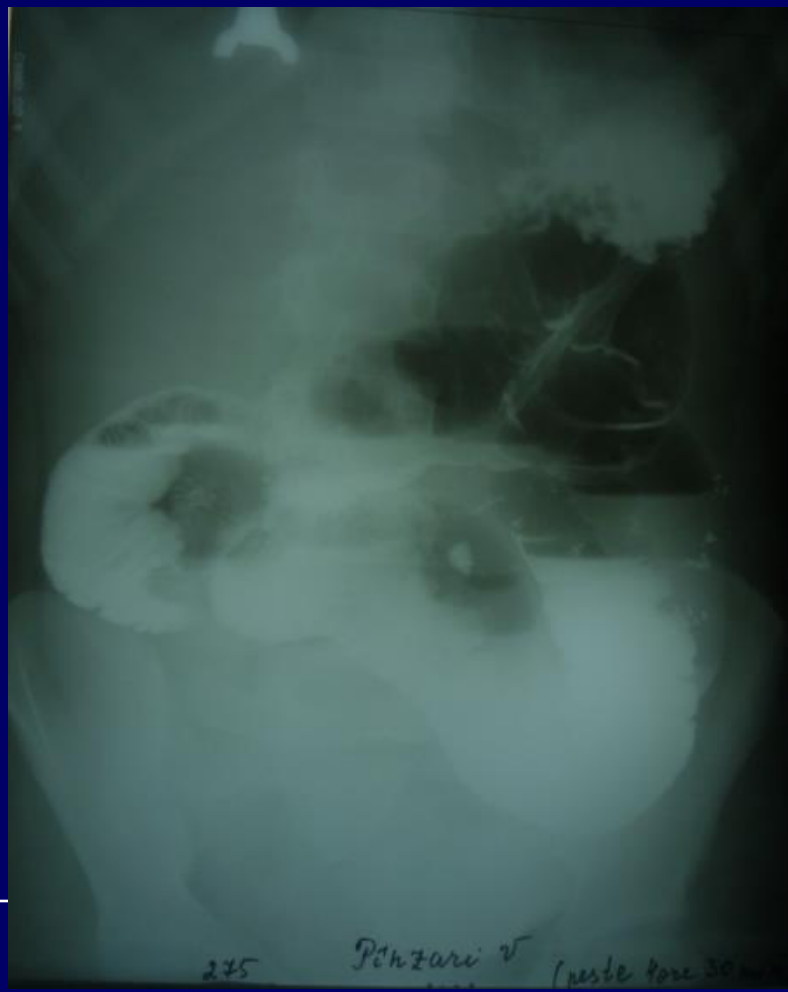
**Șef catedră – Academician A.Ș.R.M., dr.hab.șt.med., prof. universitar
Eva Gudumac**

Ocluzie intestinală

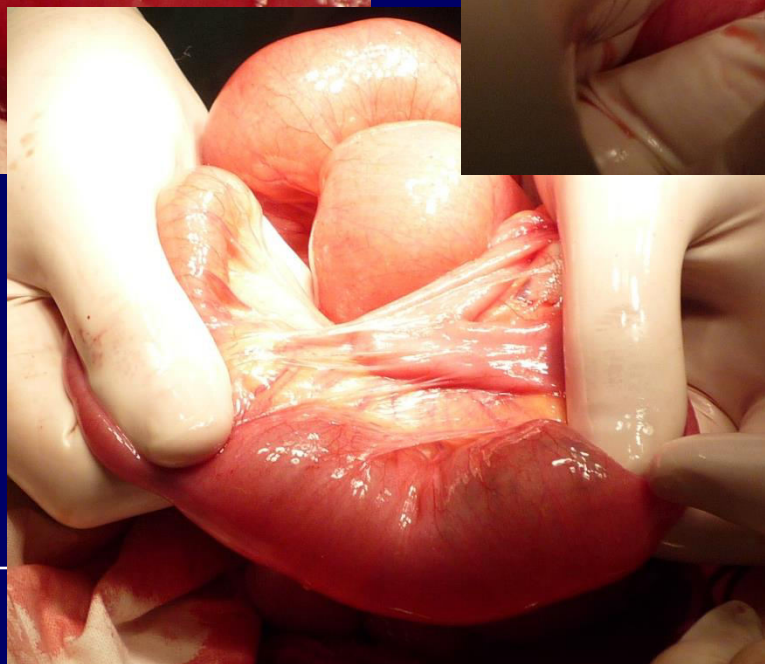
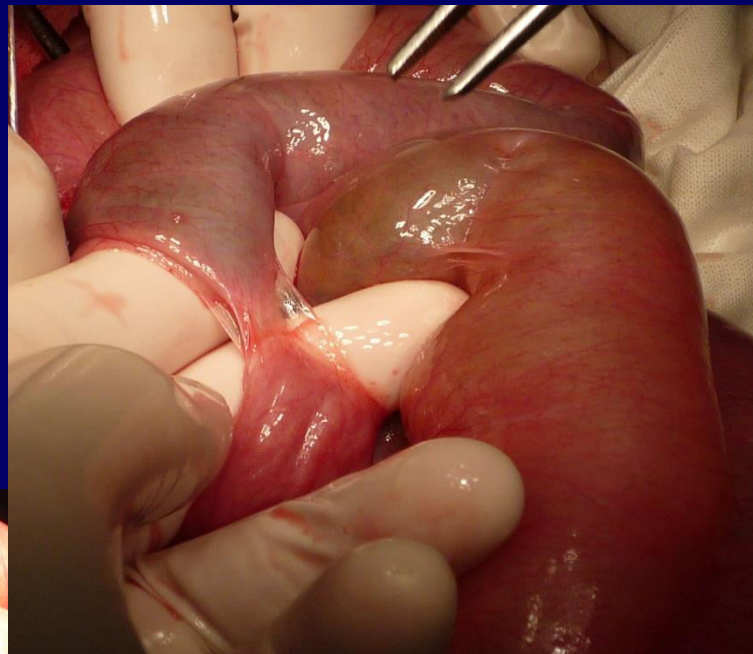
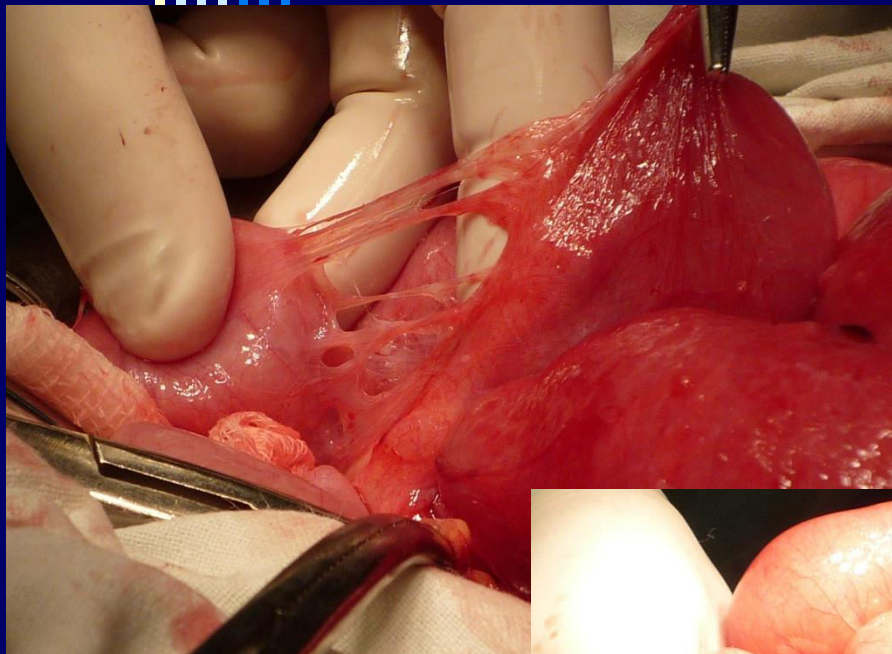
Radiografia panoramică
a organelor abdomenale



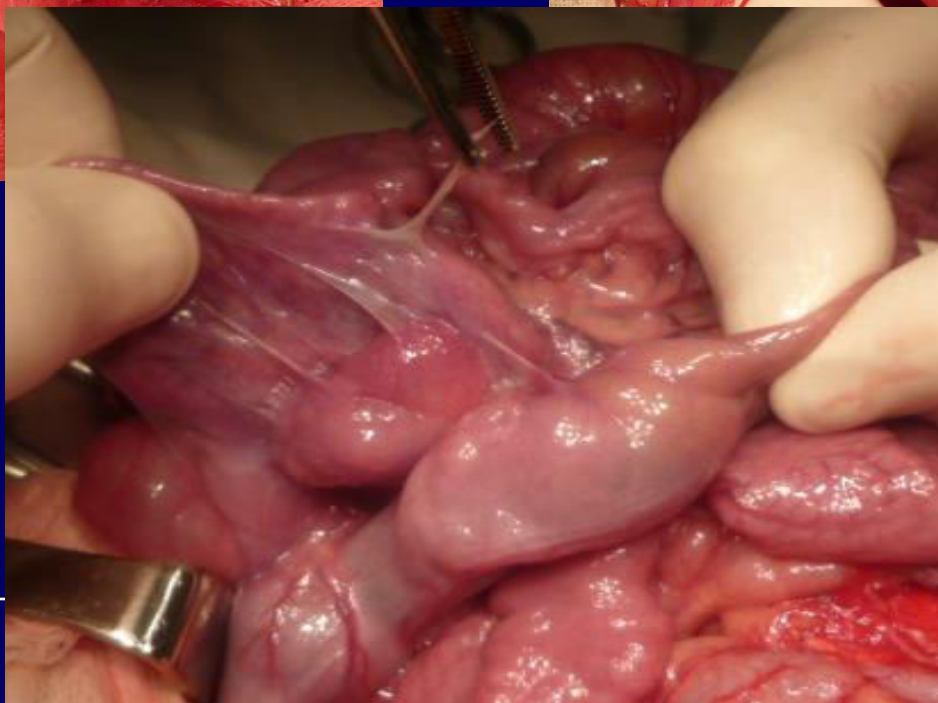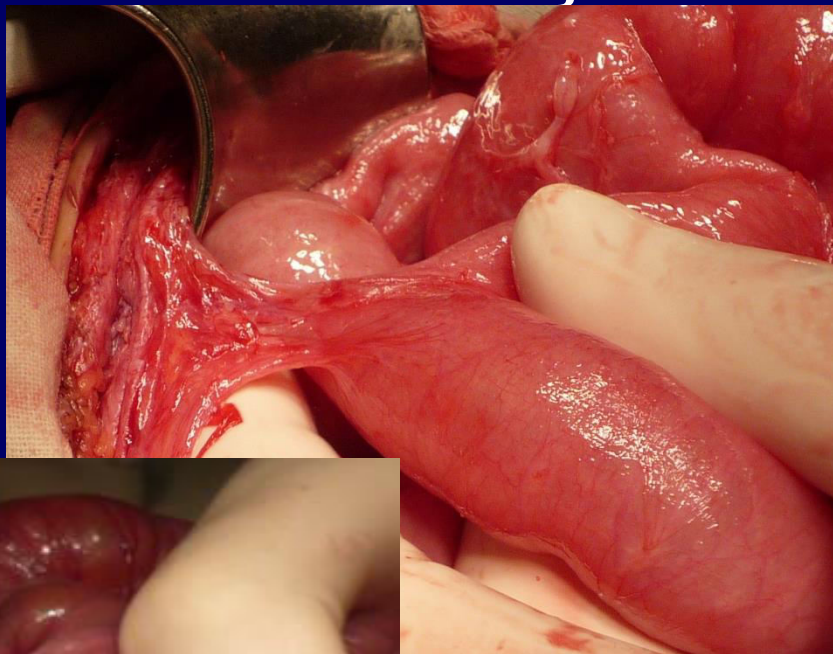
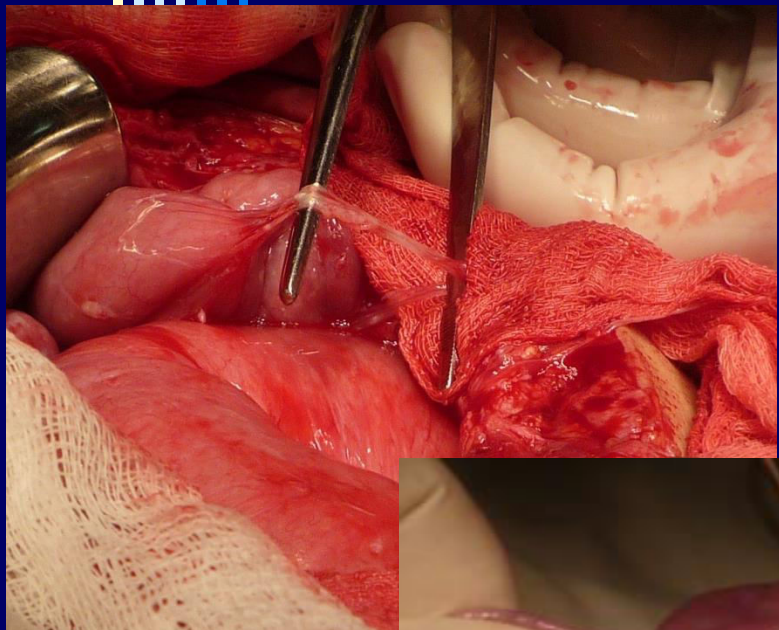
Radiografia tractului
digestiv cu masa bariatată



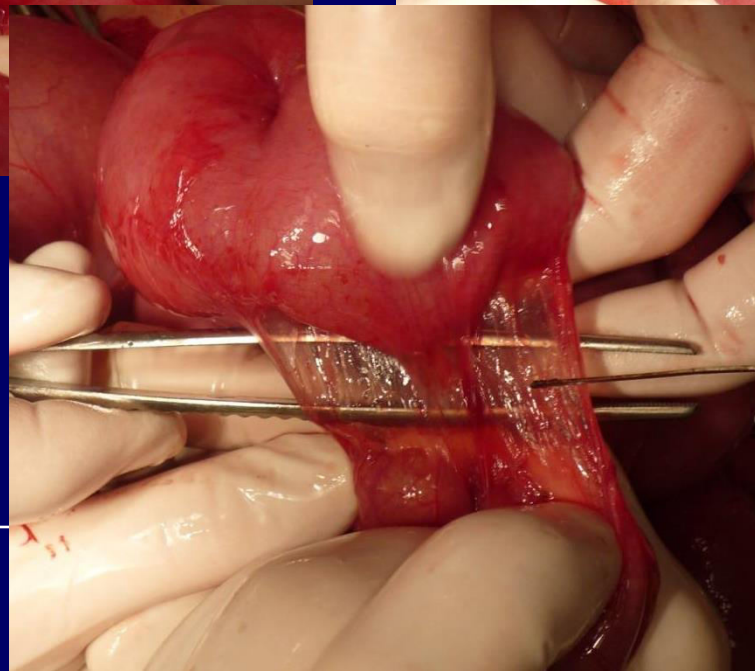
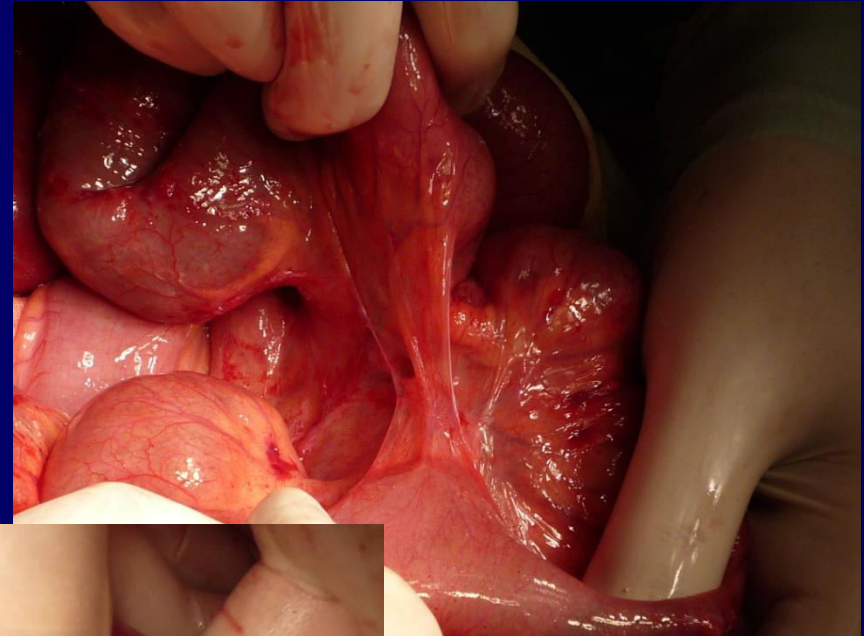
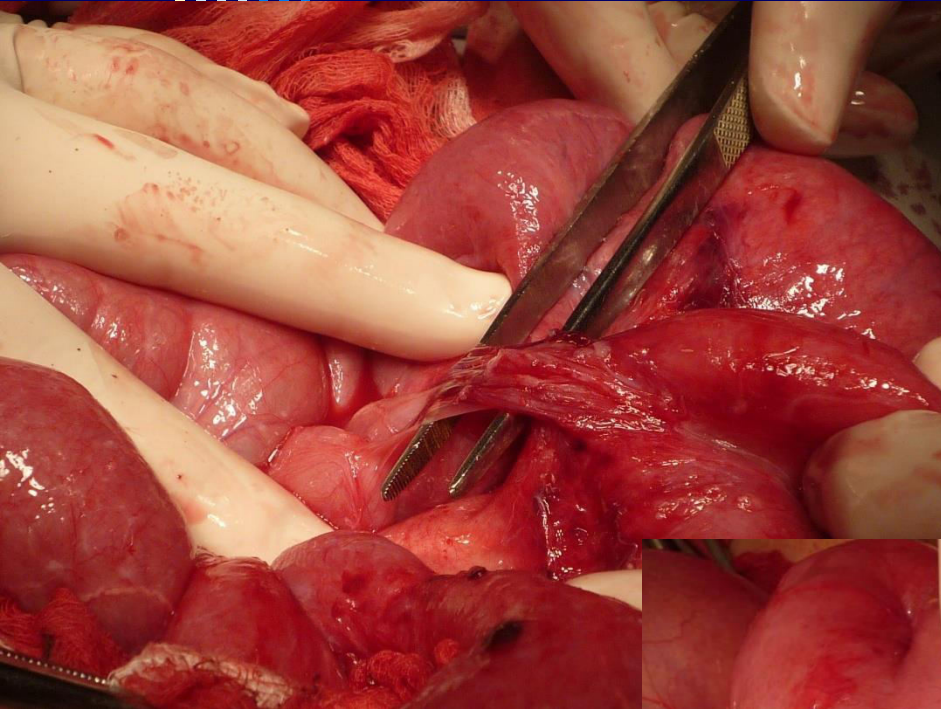
Ocluzie intestinală aderențială



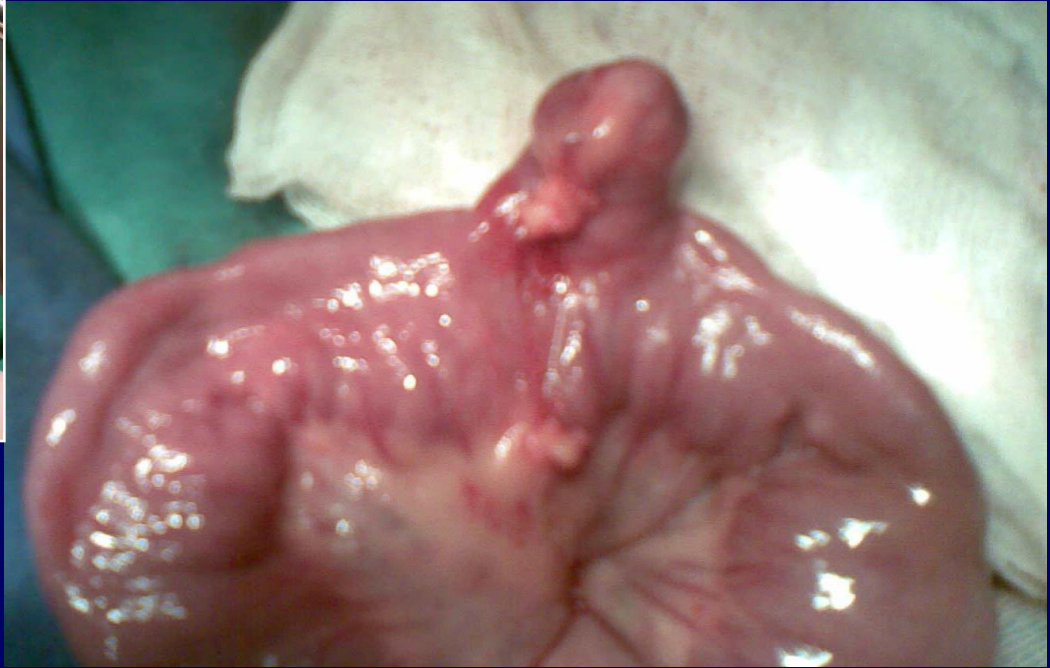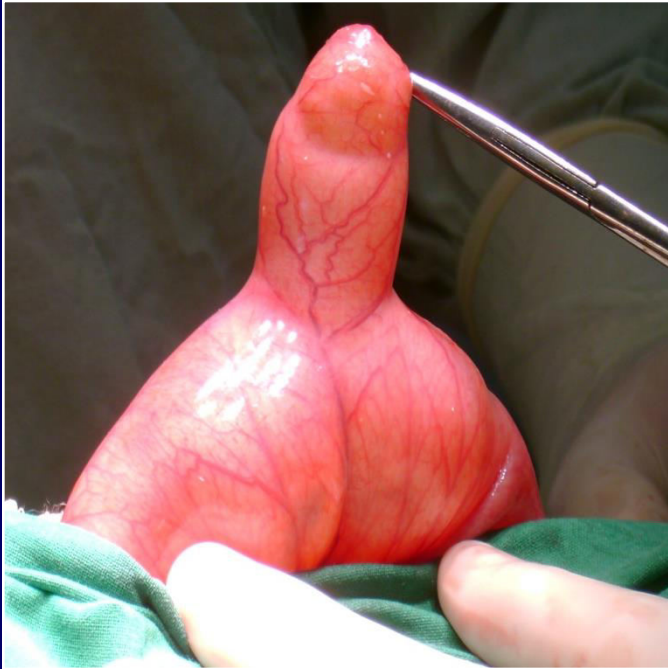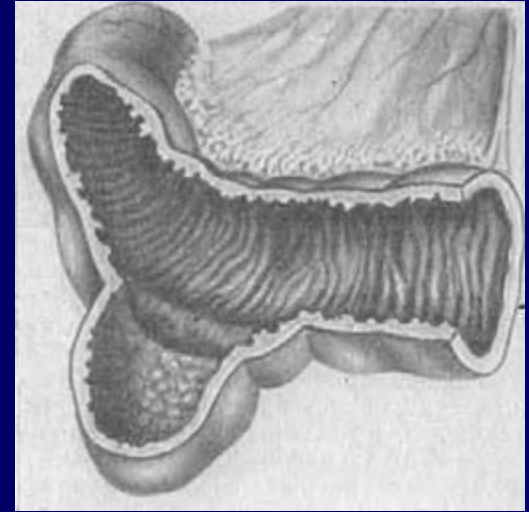
Ocluzie intestinală aderențială



Ocluzie intestinală aderențială

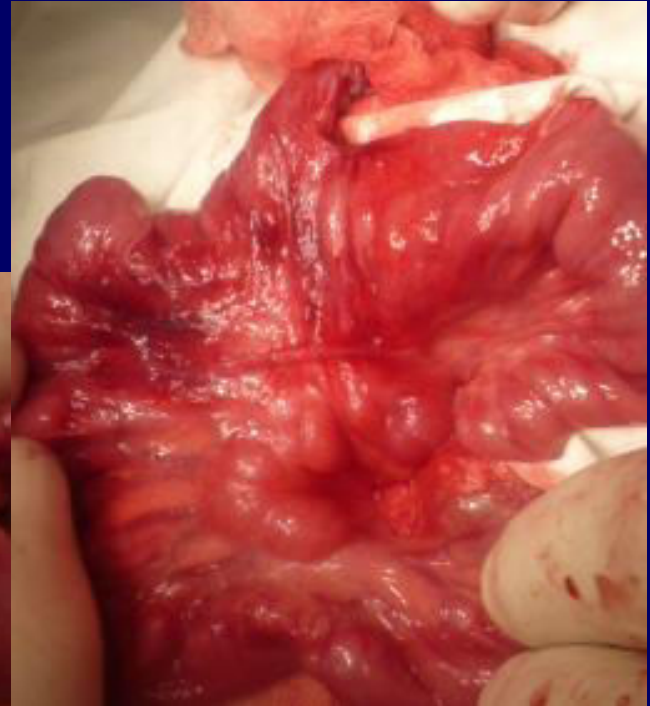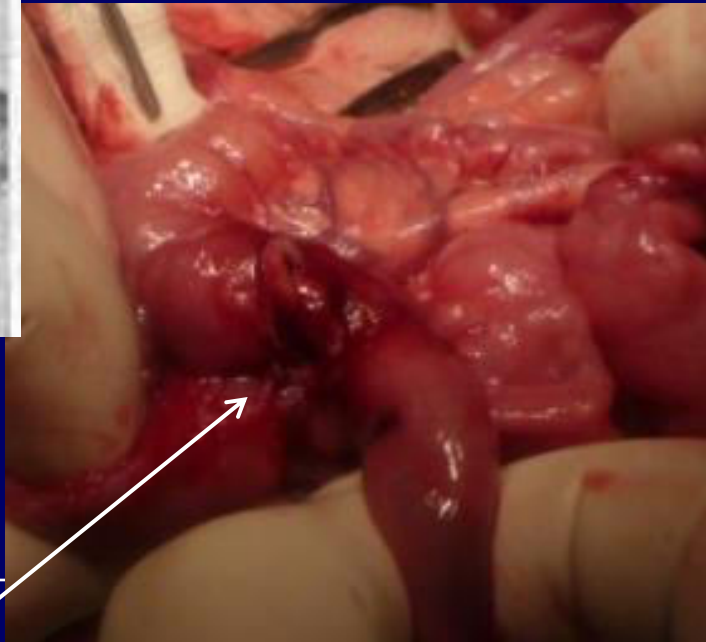

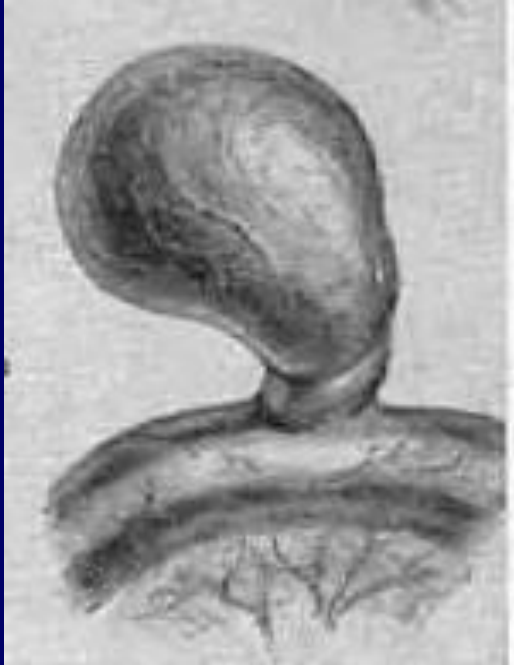
Diverticul Meckelelea



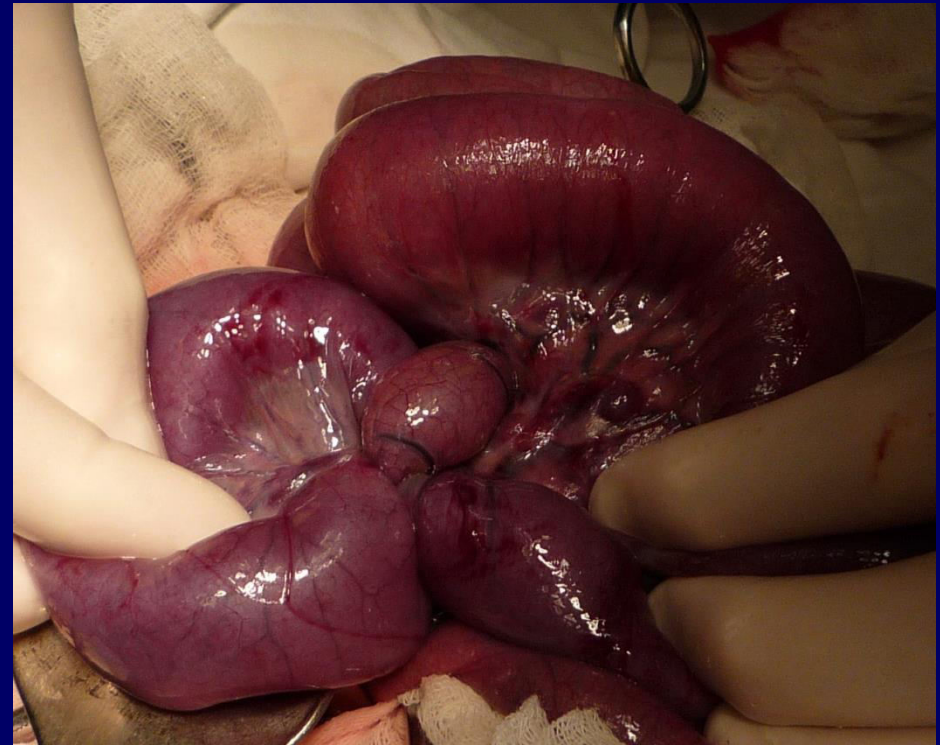
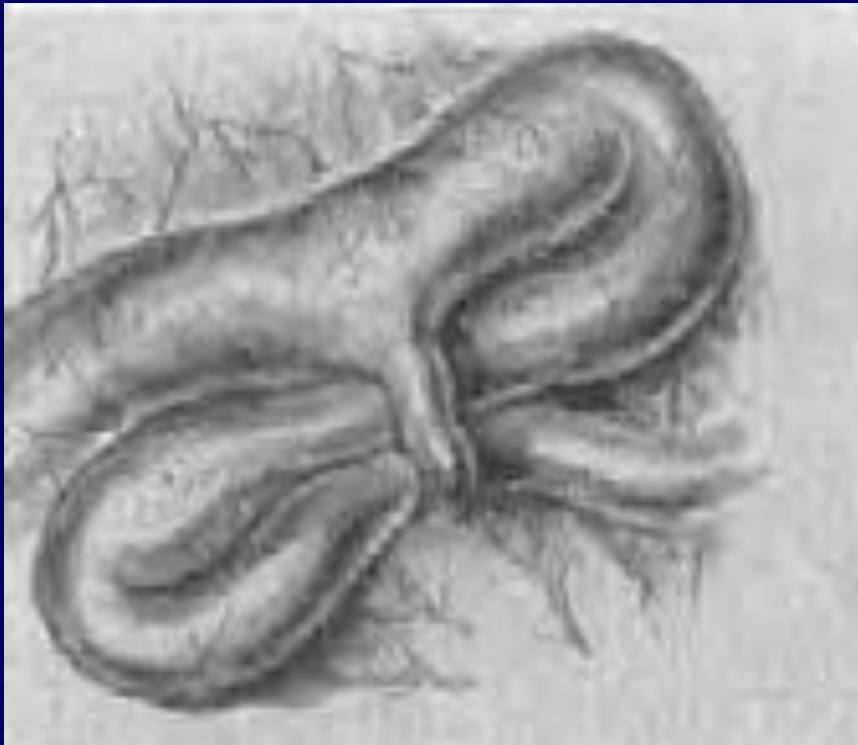Ocluzie intestinală provocată de diverticol Meckel

Volvulus diverticolului



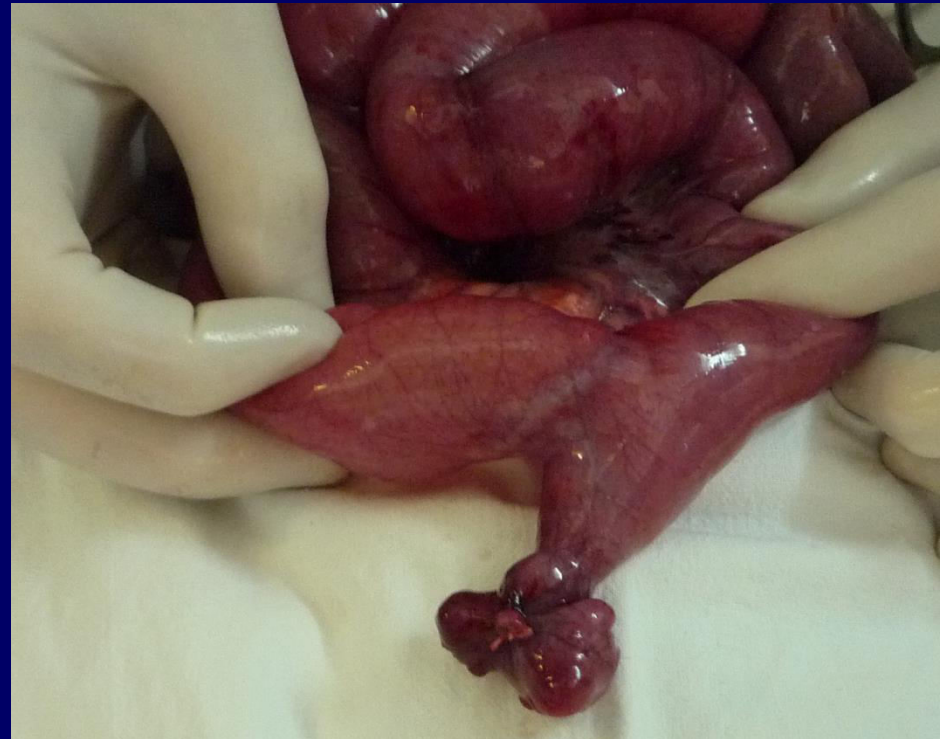
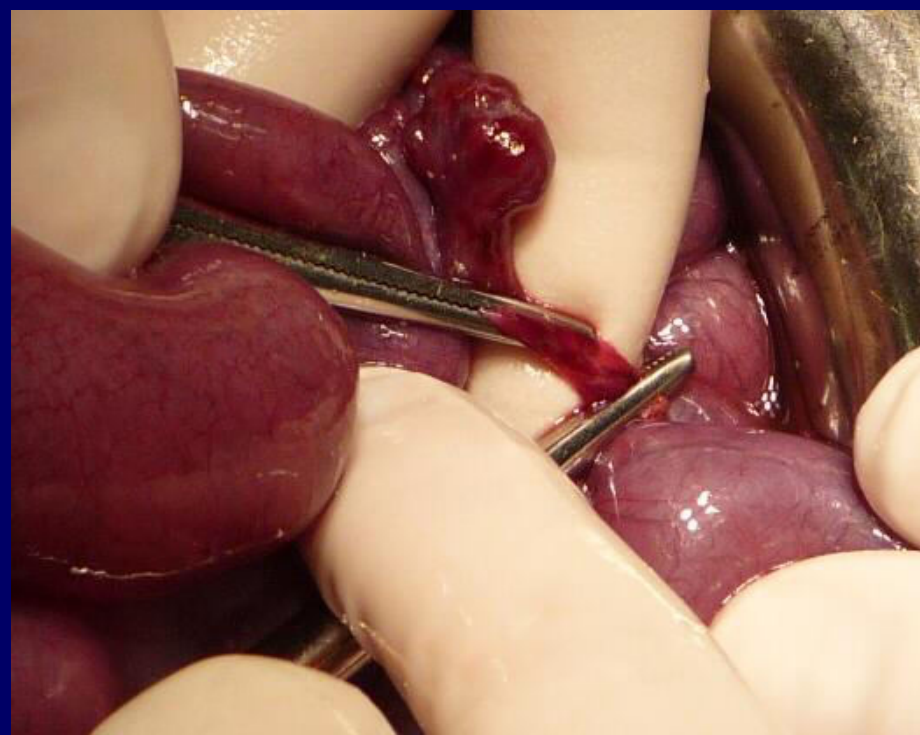
Ocluzie intestinală provocată de diverticol Mekhel

Strangularea intestinului subțire către diverticol



Ocluzie intestinală provocată de diverticol Meckel

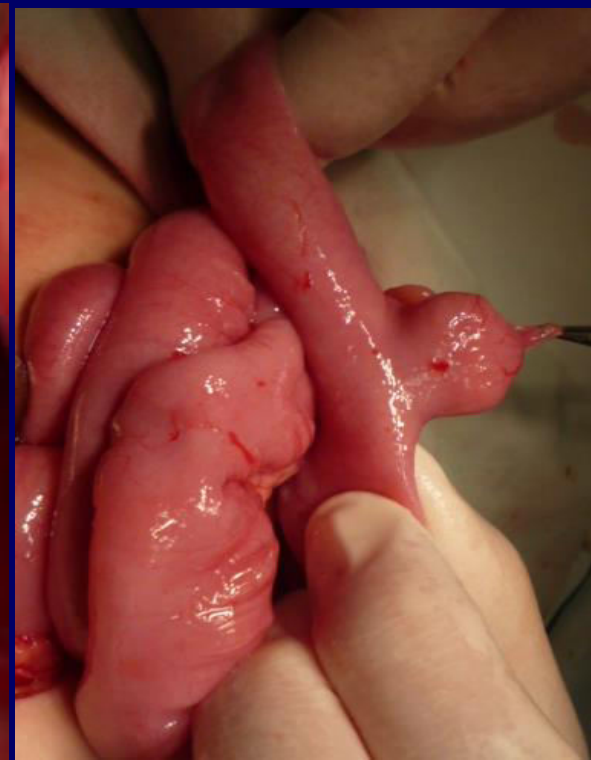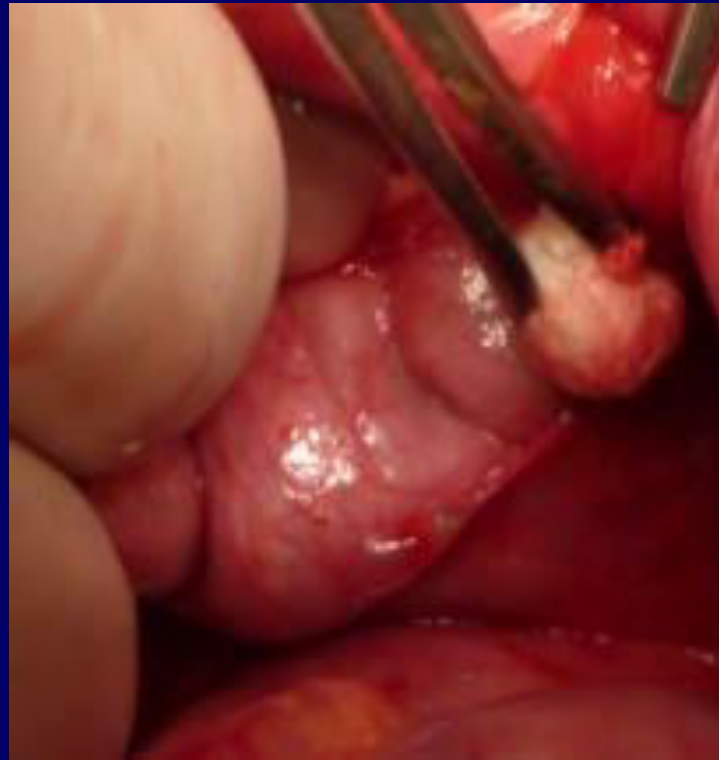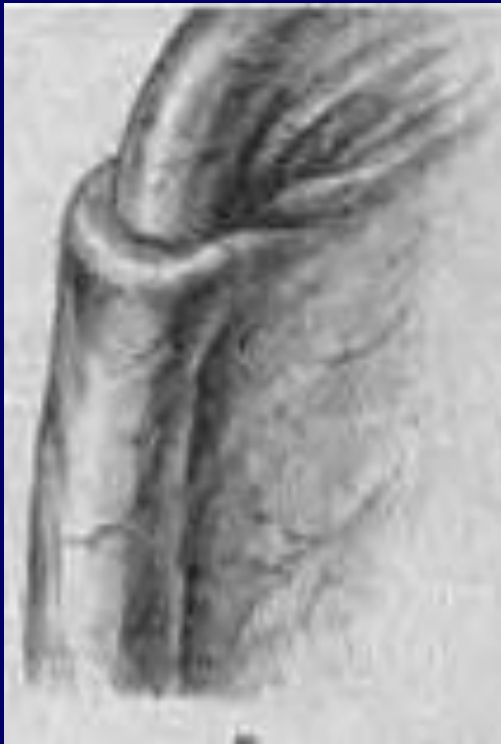Strangularea intestinului subțire către diverticol



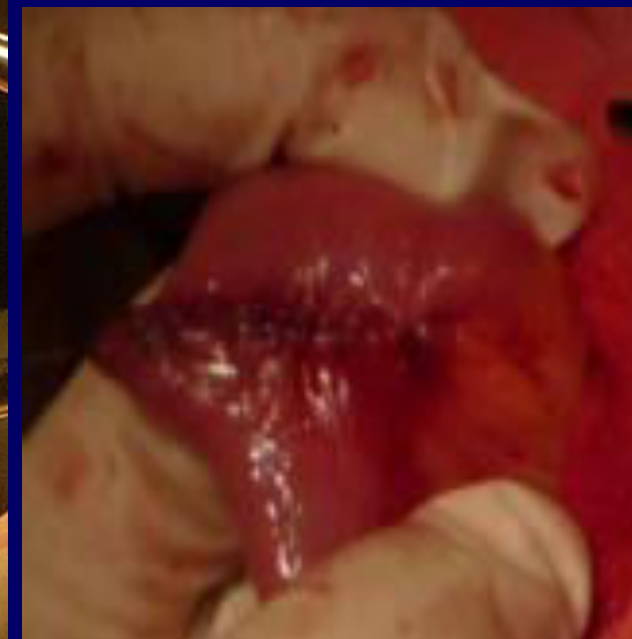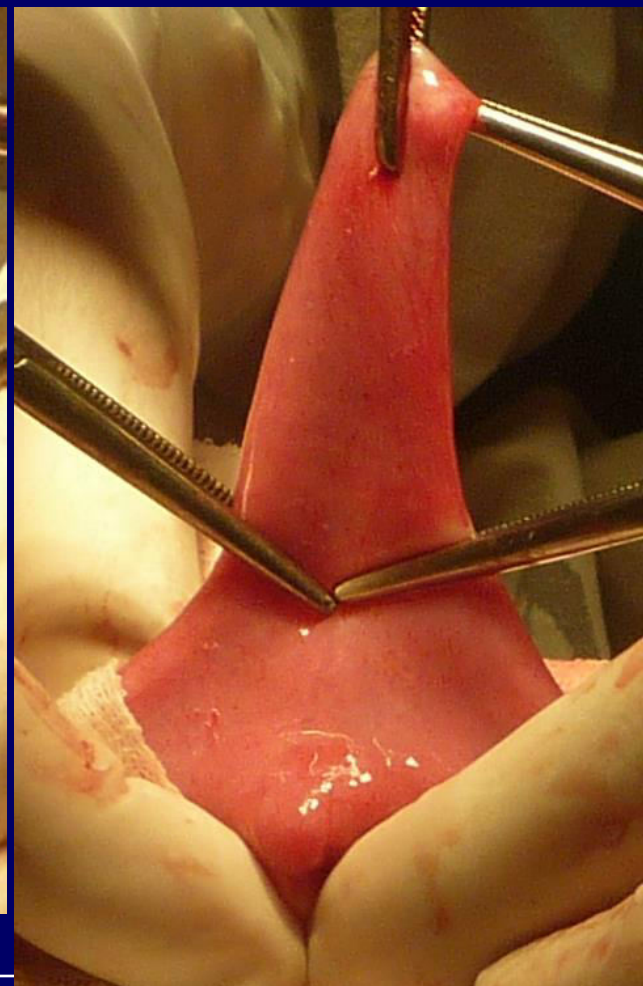
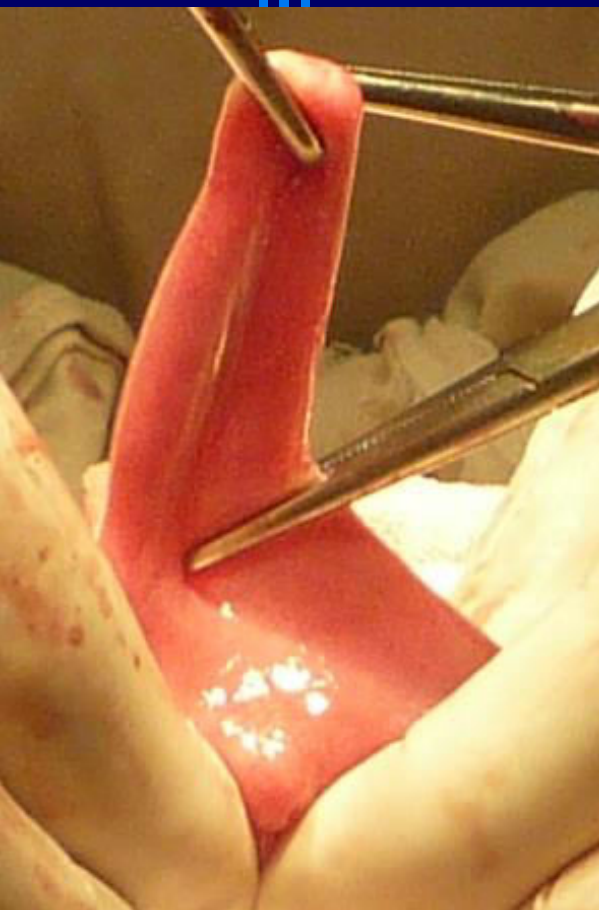


Ocluzie intestinală provocată de diverticol Meckel

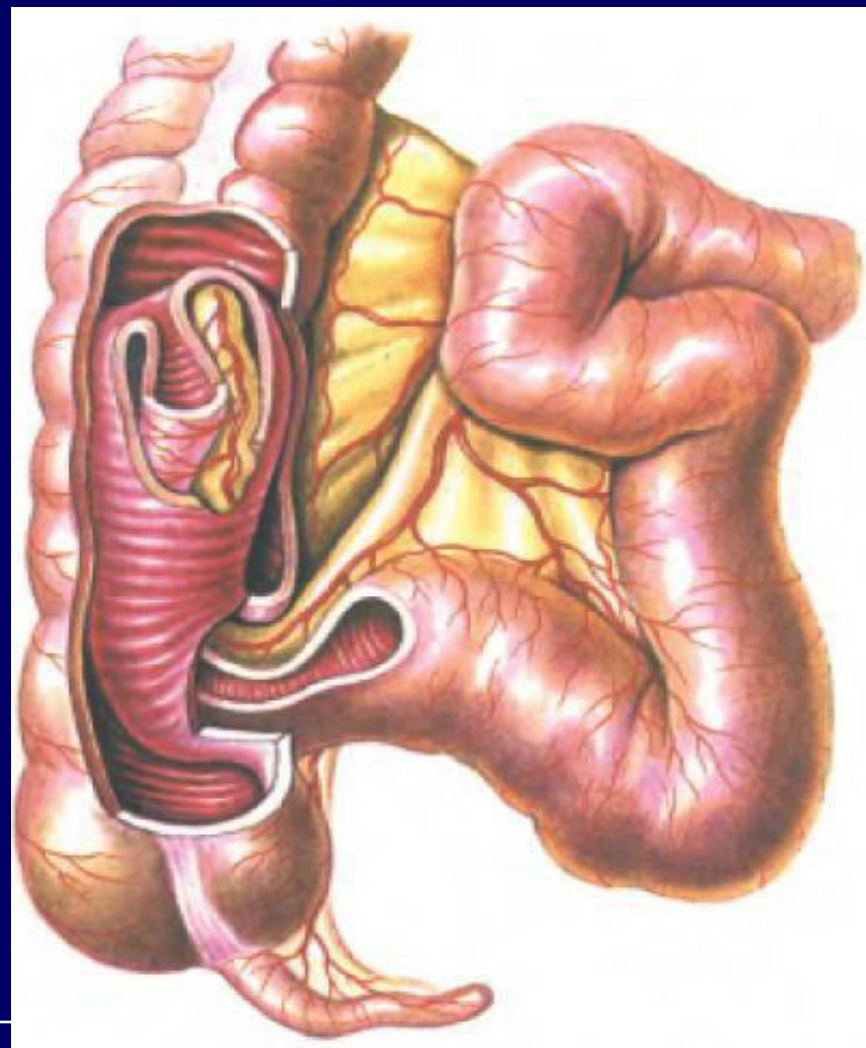
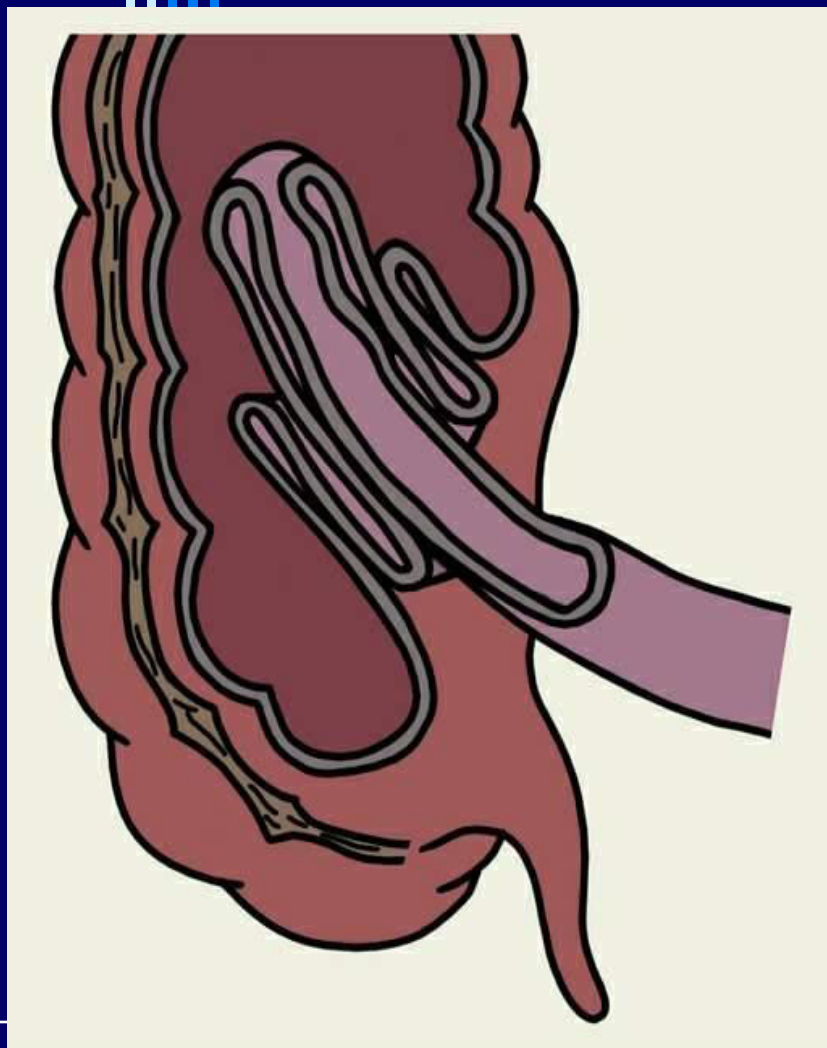
Invaginația intestinului provocată de diverticol



Tratament diverticolului Meckel



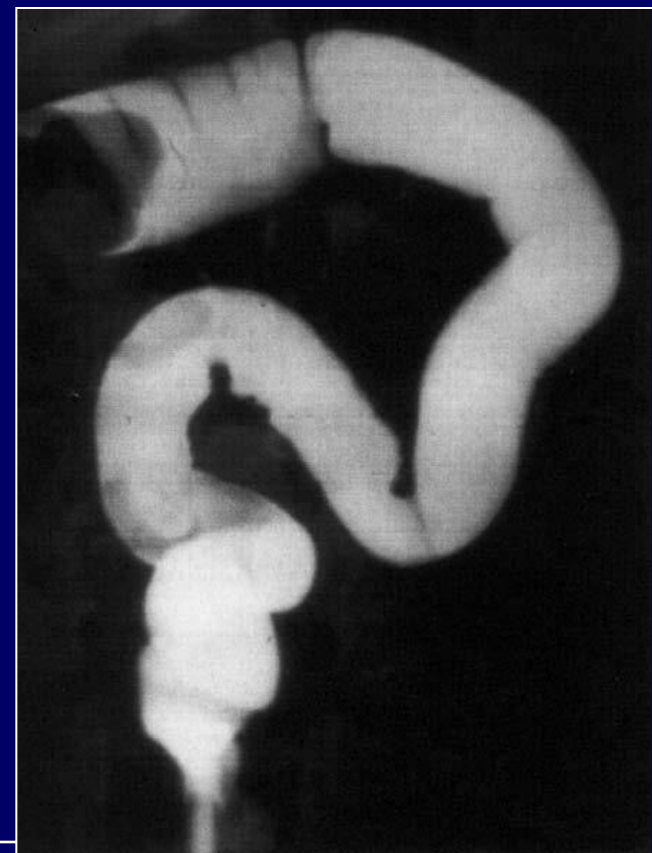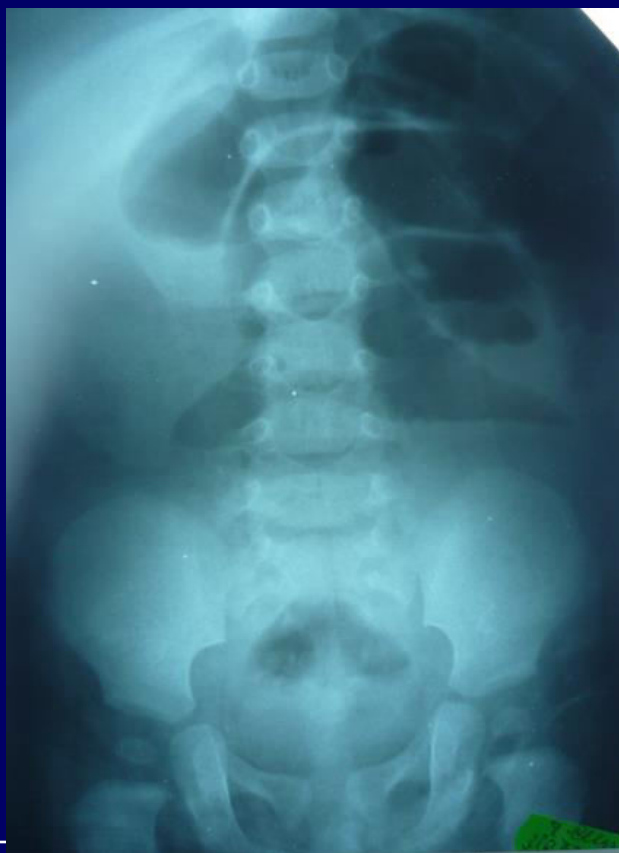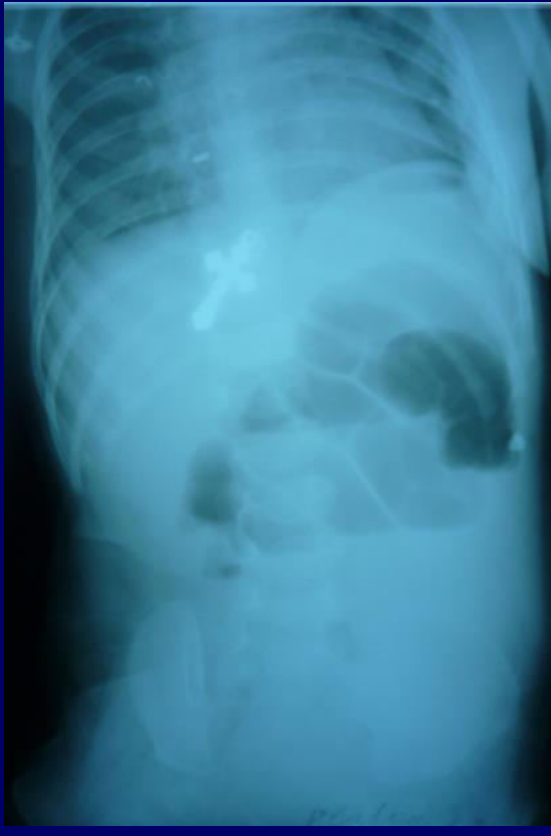INVAGINAȚIA INTESTINALĂ



INVAGINAȚIA INTESTINALĂ

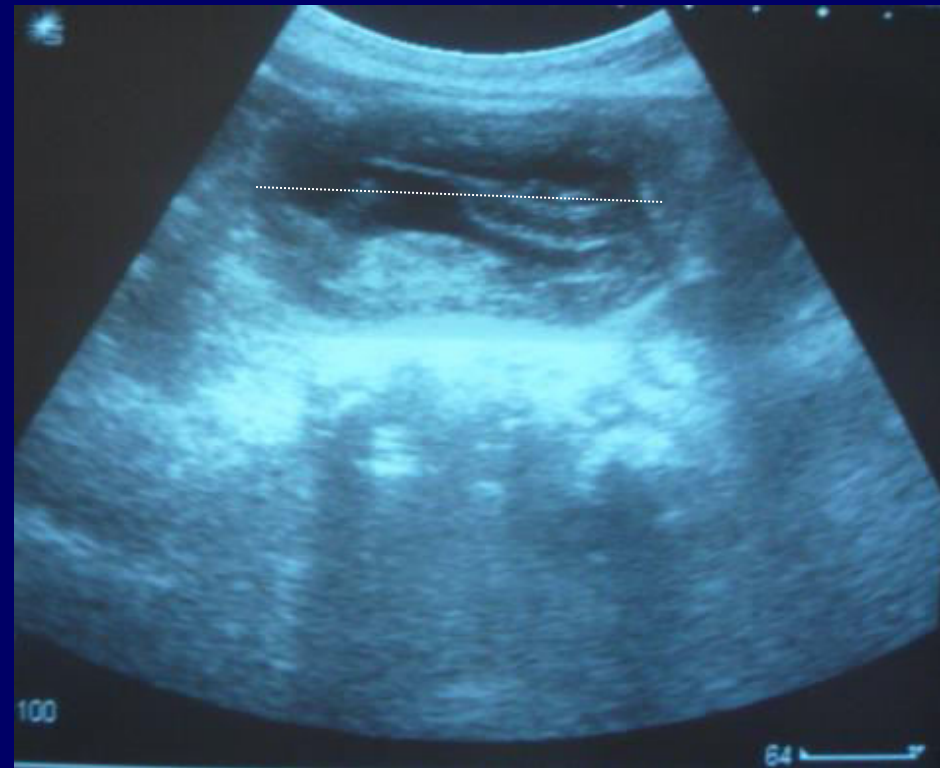
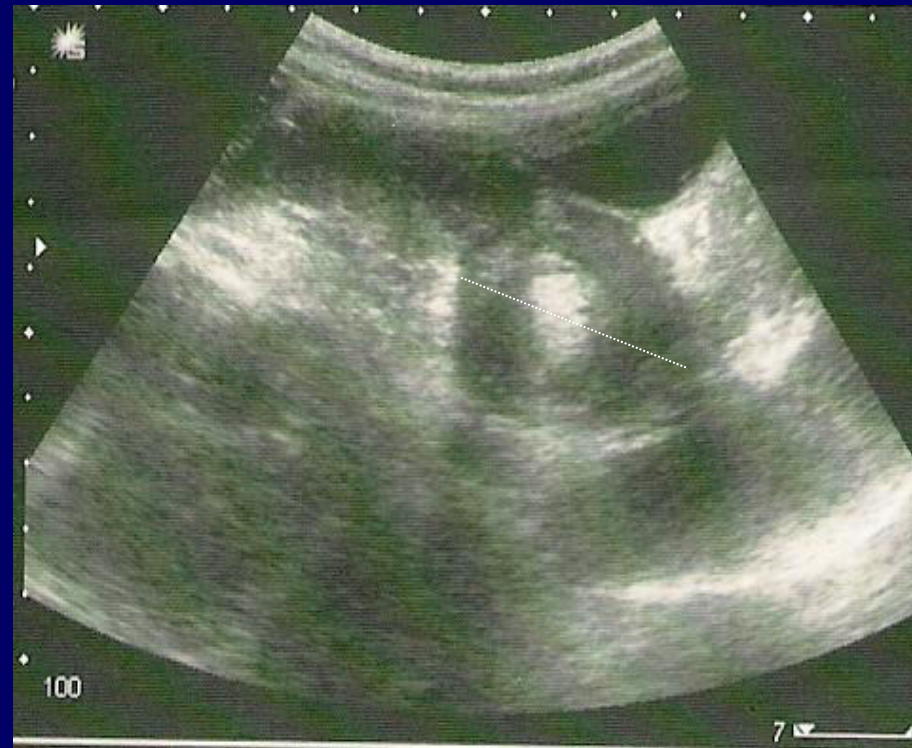**Radiografia panoramică a
organelor abdomenale**

Irigografia

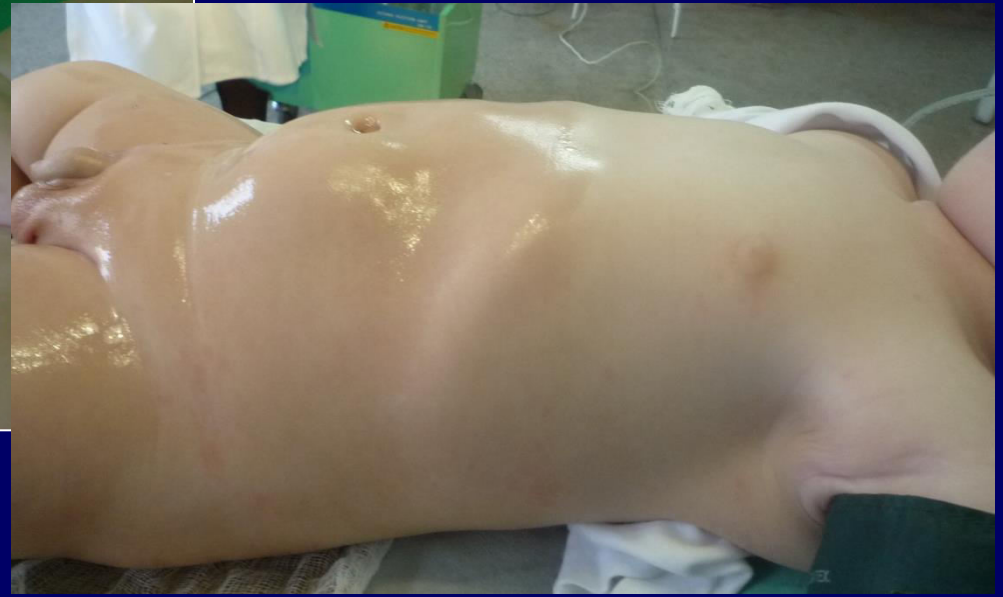
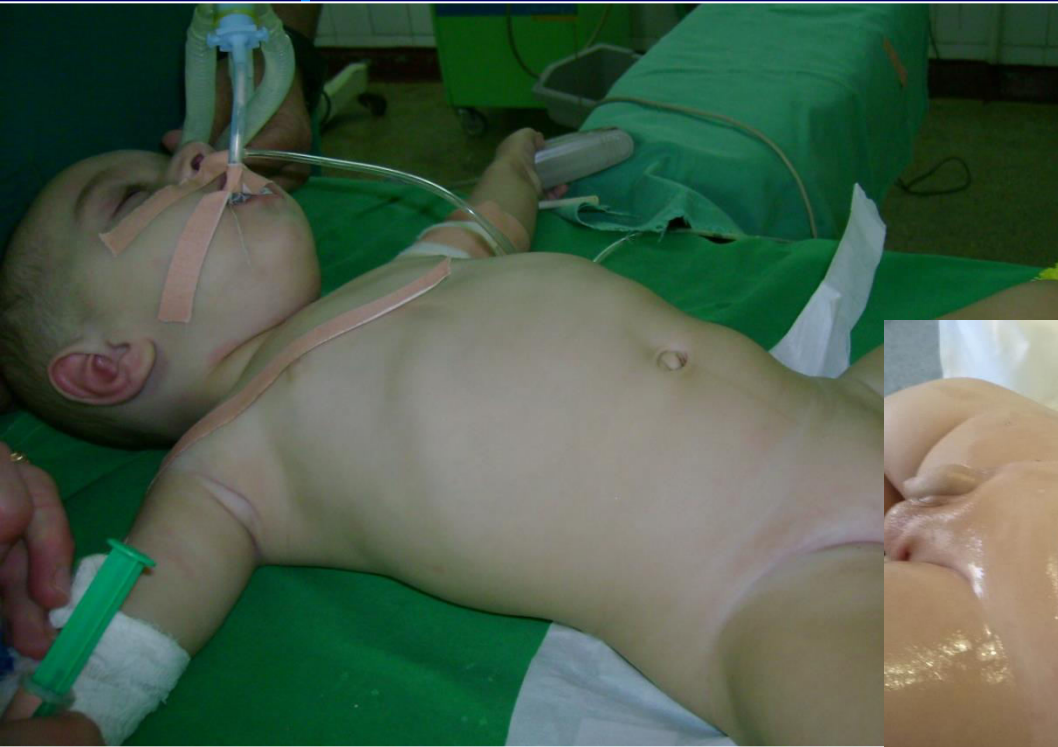
INVAGINAȚIA INTESTINALĂ

USG



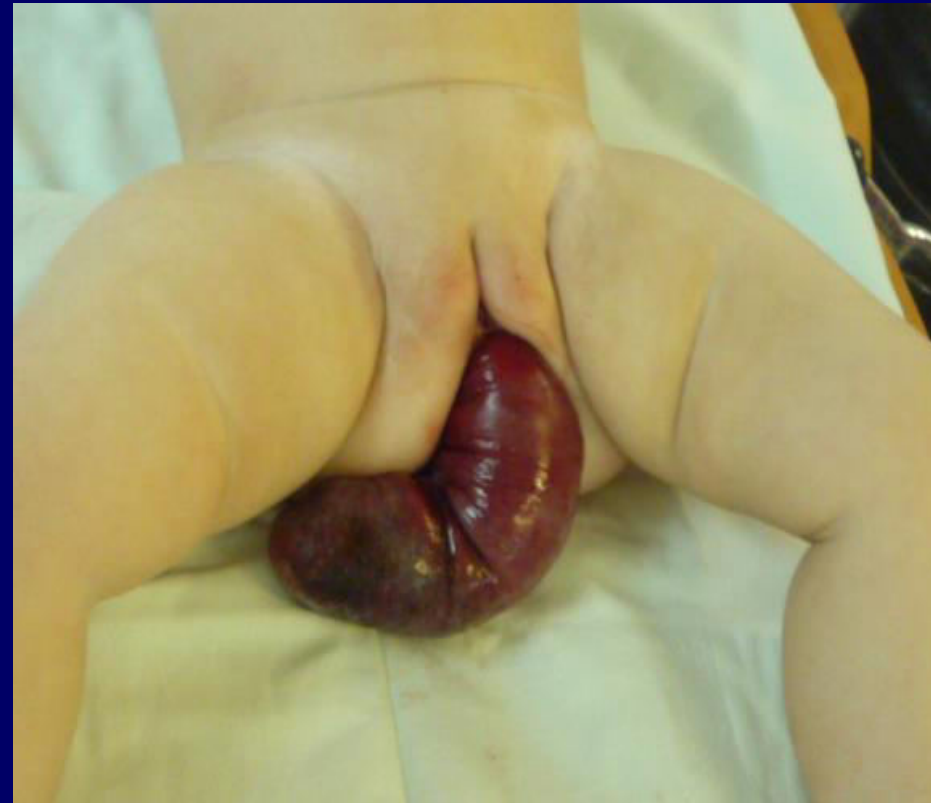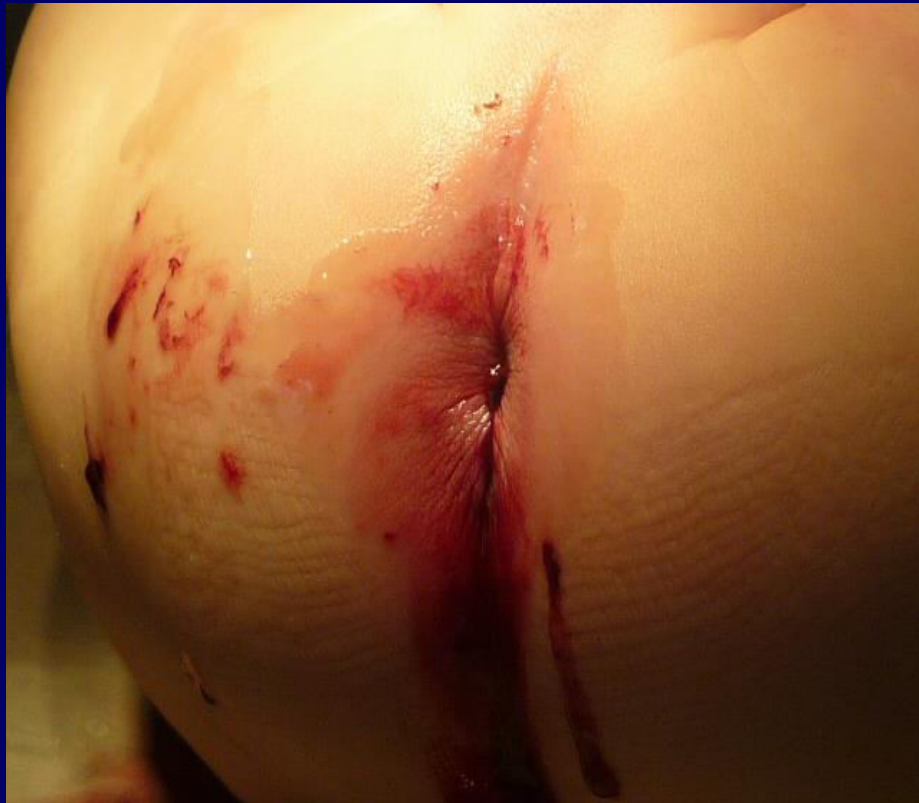Obiectiv



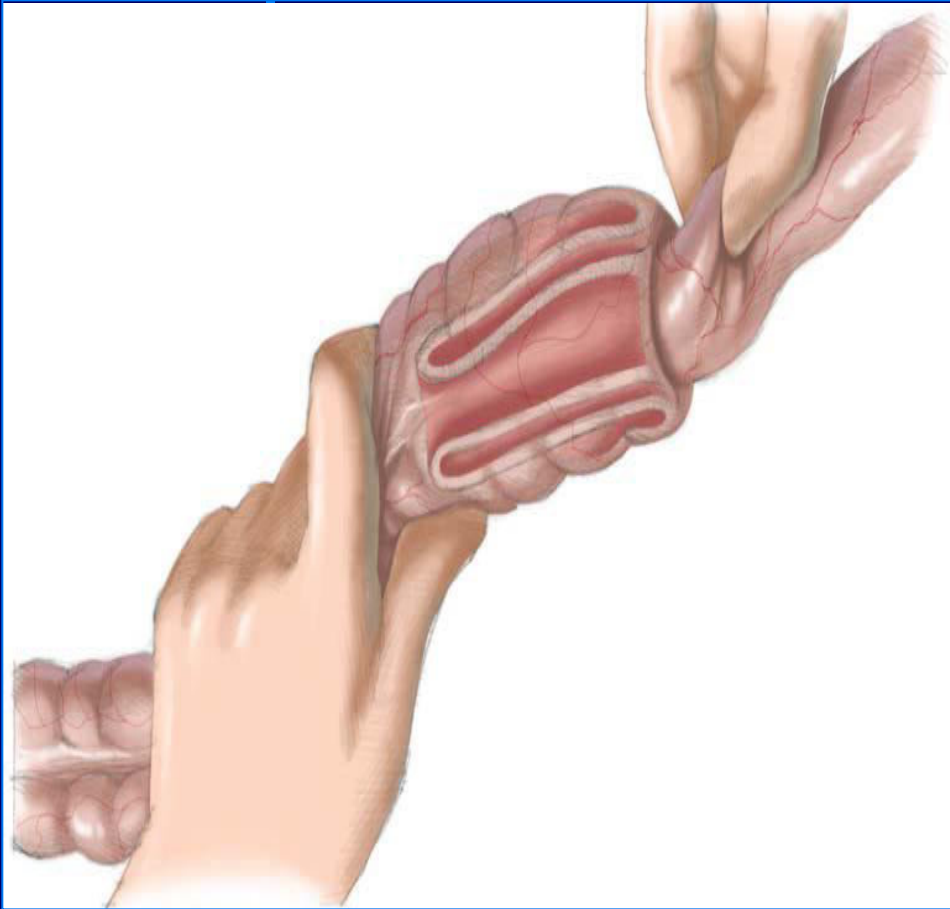
Obiectiv

Elinimarea sîngei
neschimbate prin orificiul
anal

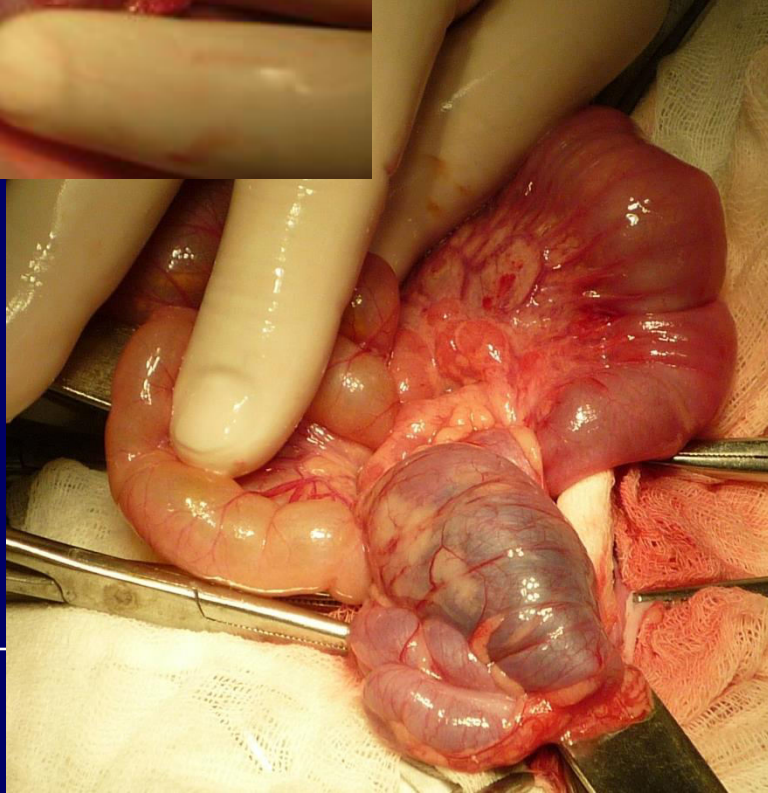
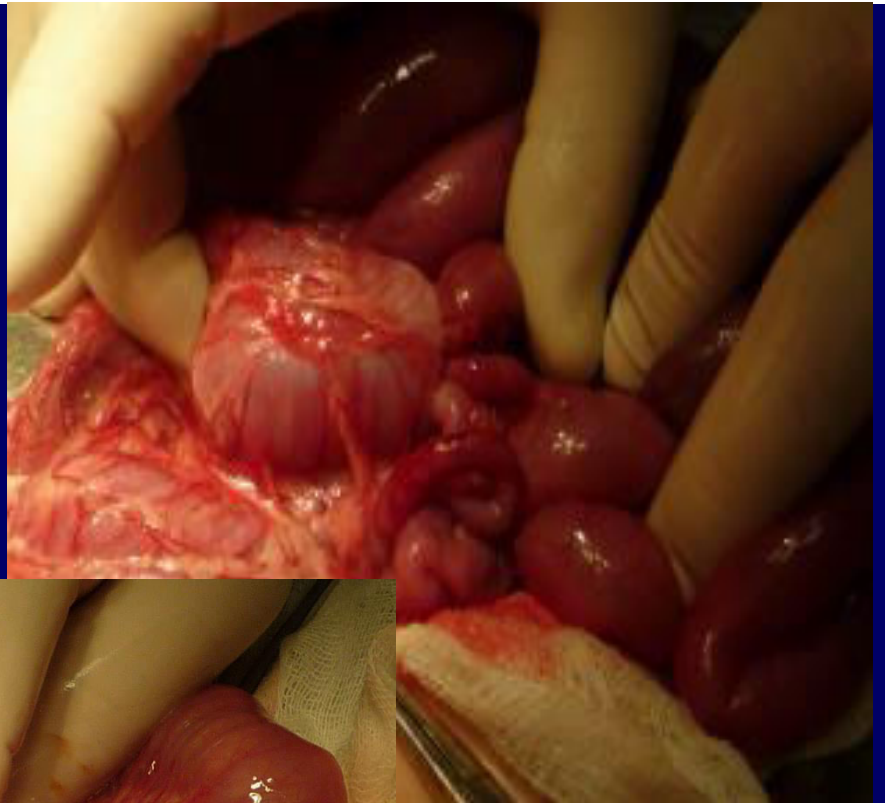
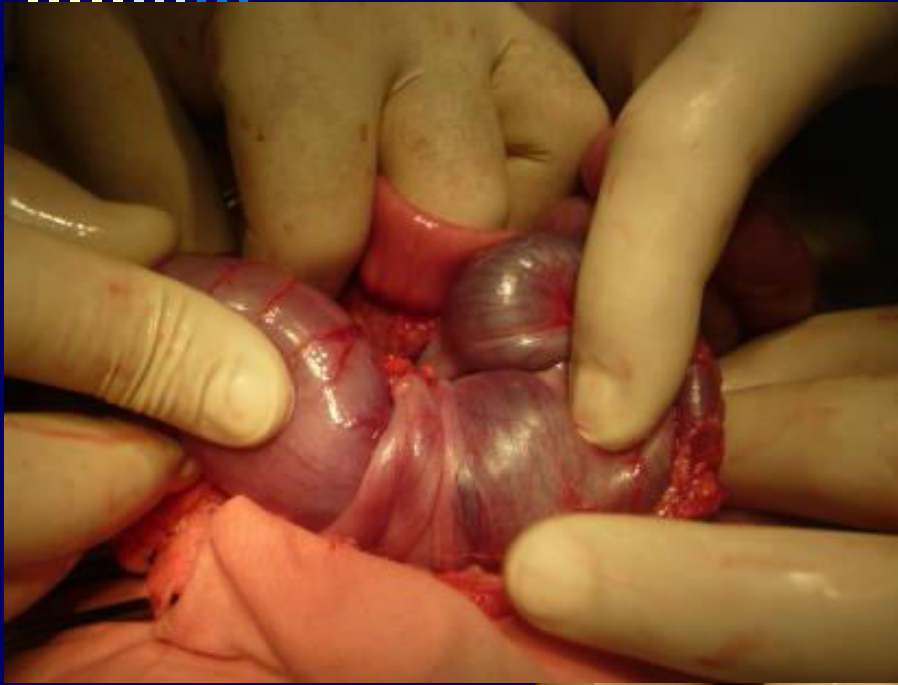Prolabarea invaginatului
prin orificiul anal



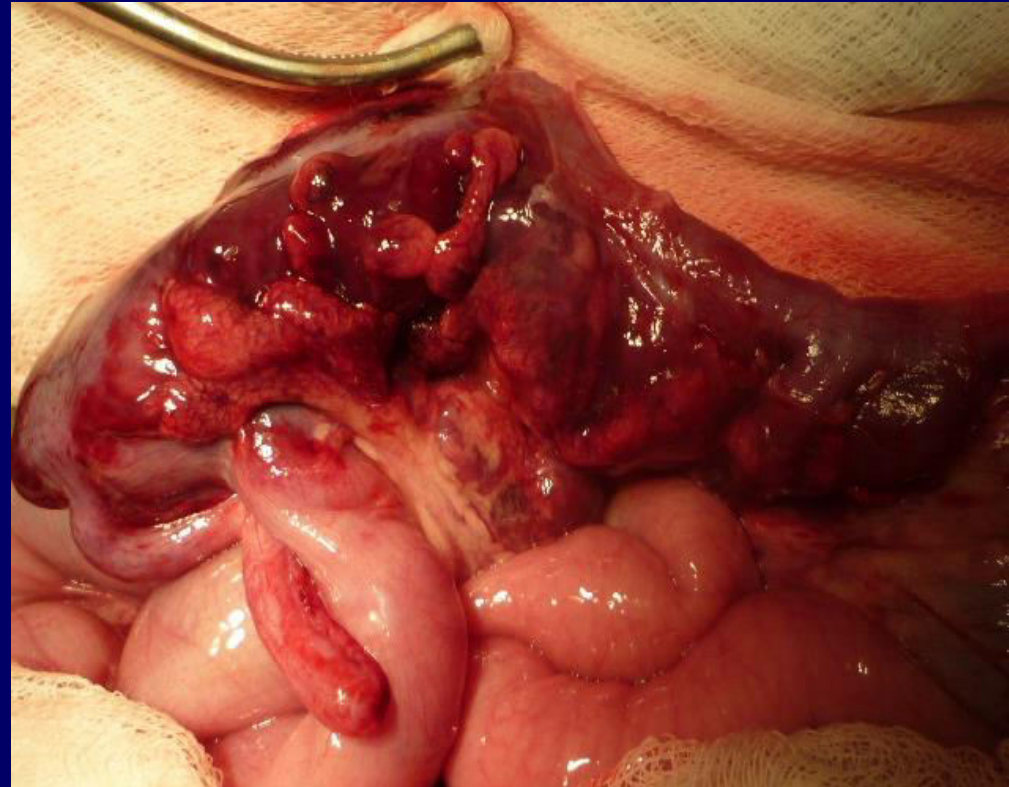
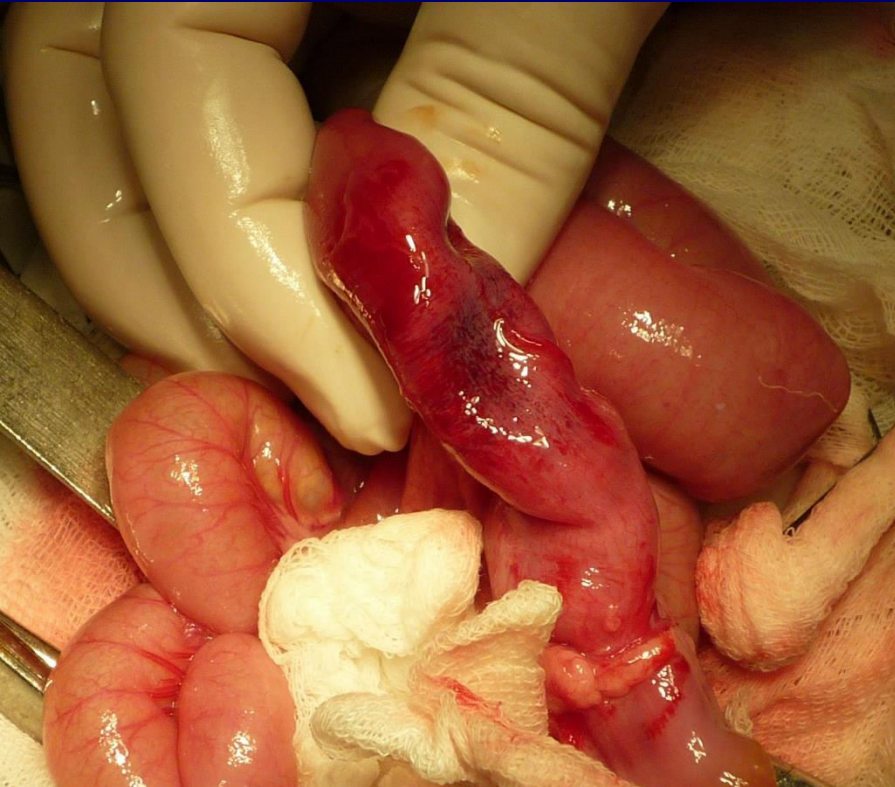Tratament



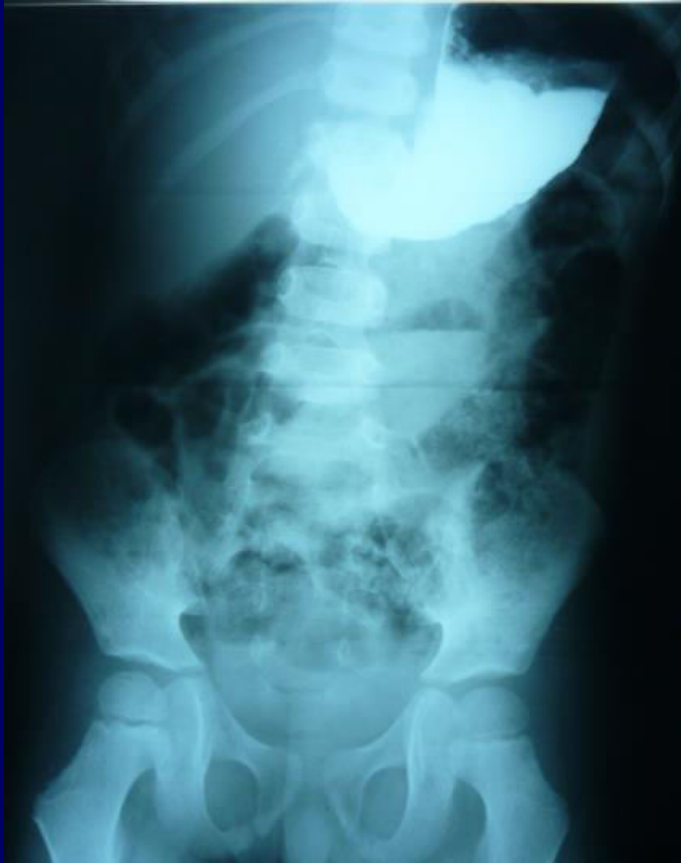Dezinvaginarea
prin “mulgere”
a invaginatului



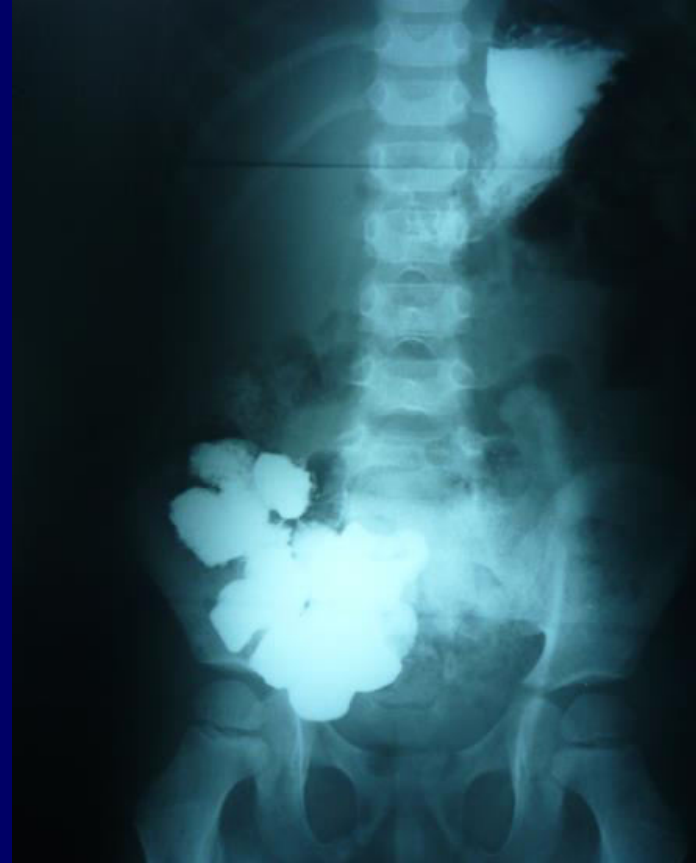Intestinul după dezinvaginație



Anomalie de fixare jejunului

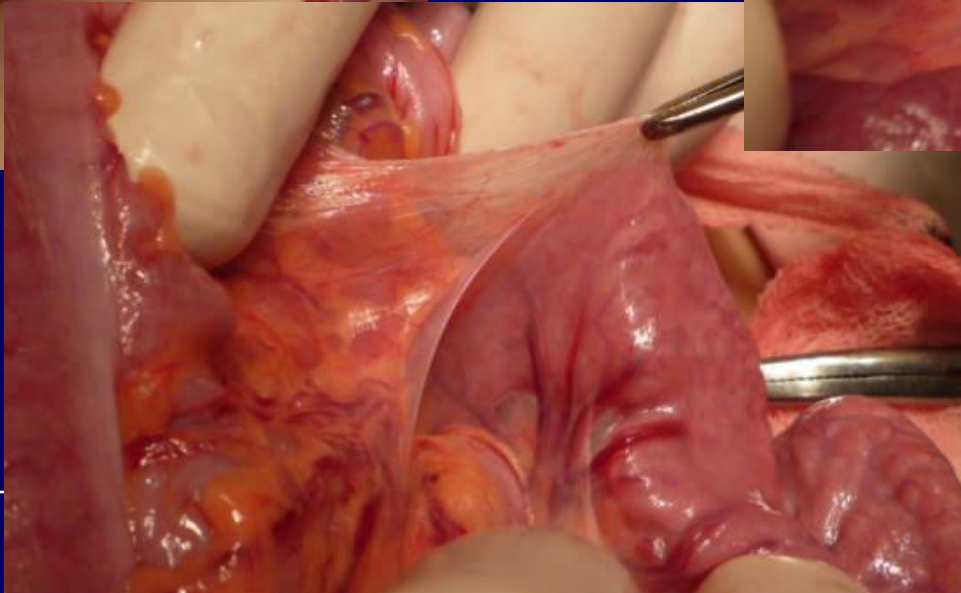
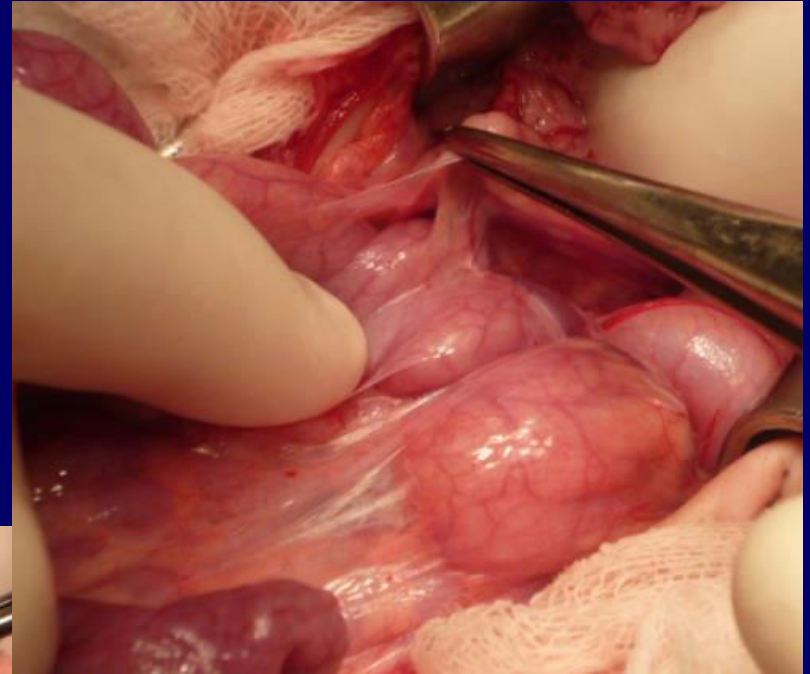
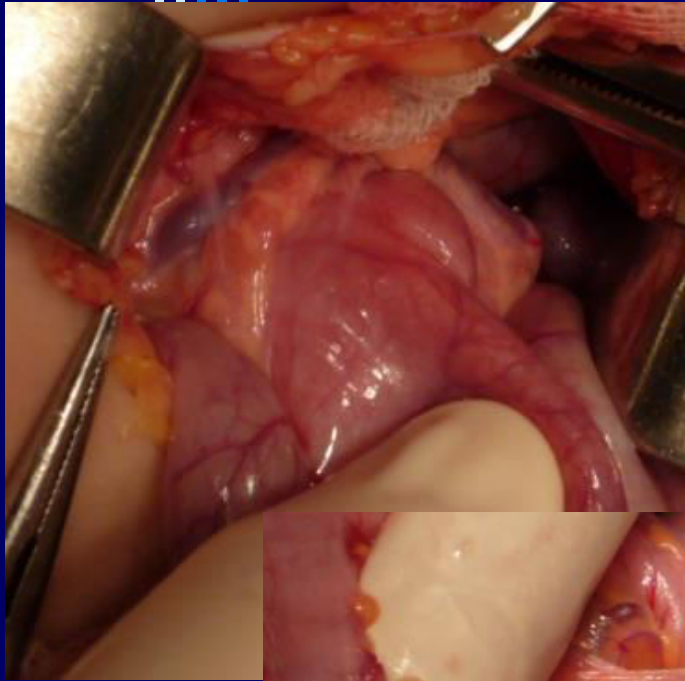


Radiografia tractului digestiv
cu masa bariatată peste 3 ore

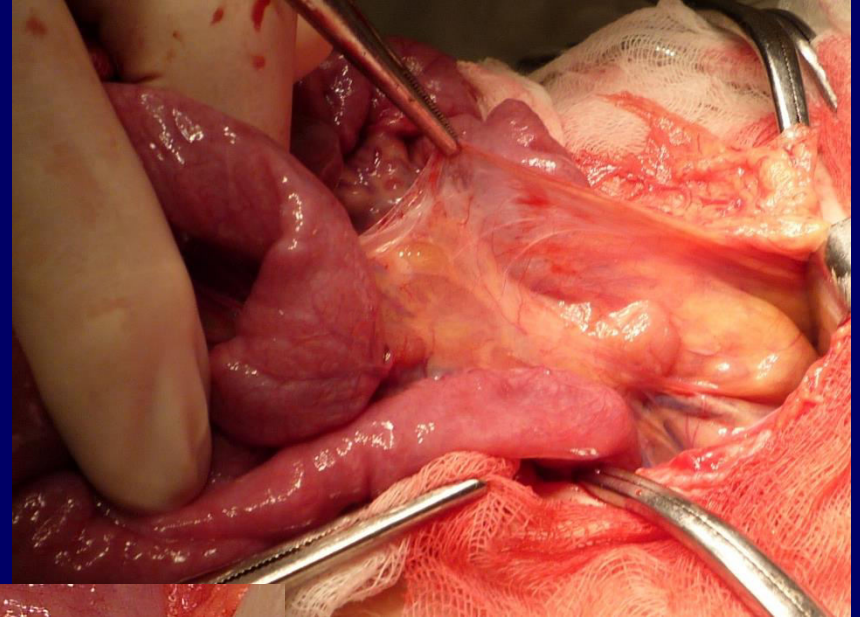
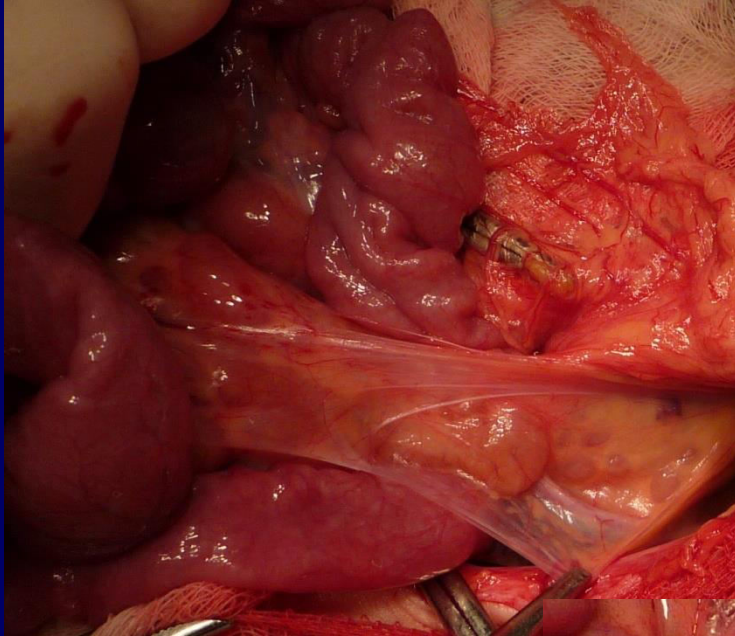


Radiografia tractului digestiv
cu masa bariatată peste 9 ore

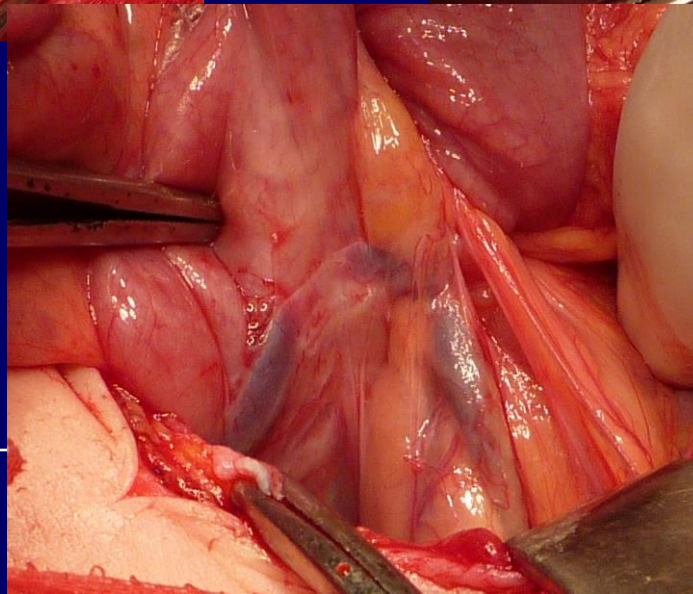
Anomalie de fixare jejunului



Anomalie de fixare jejunului



**Comprimarea și
deformarea
Venei mezenterice**



Torsia intestinului

